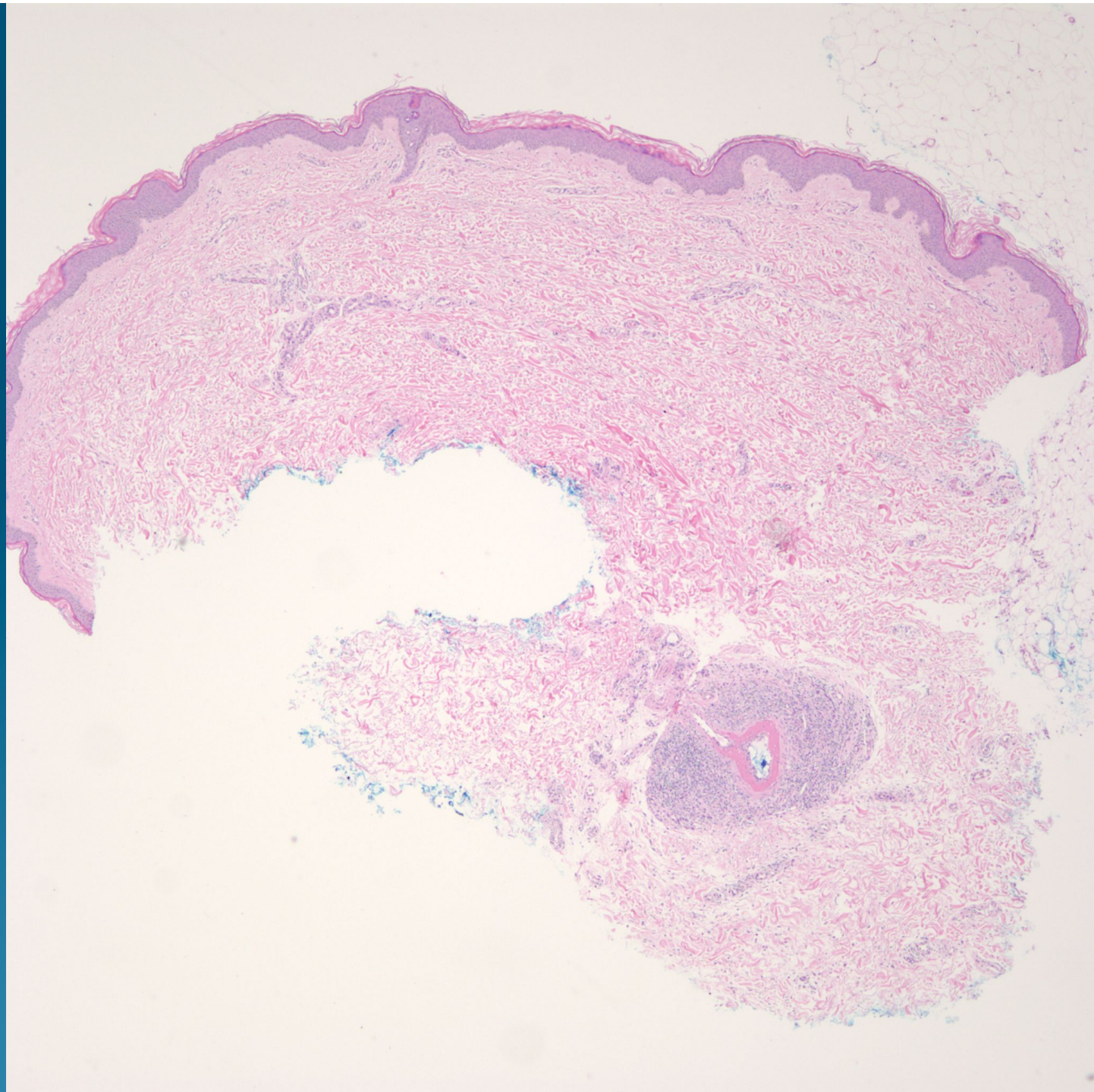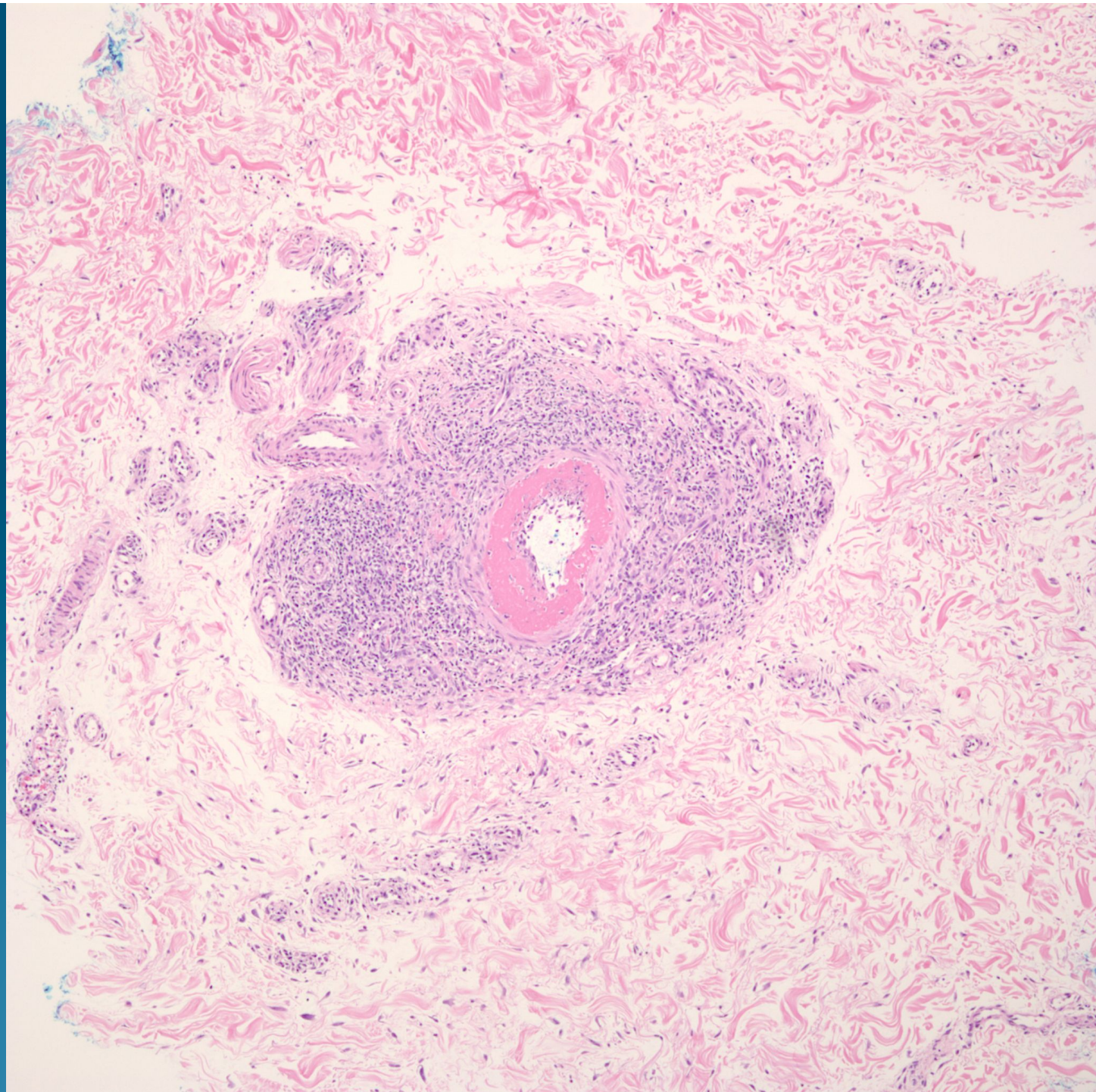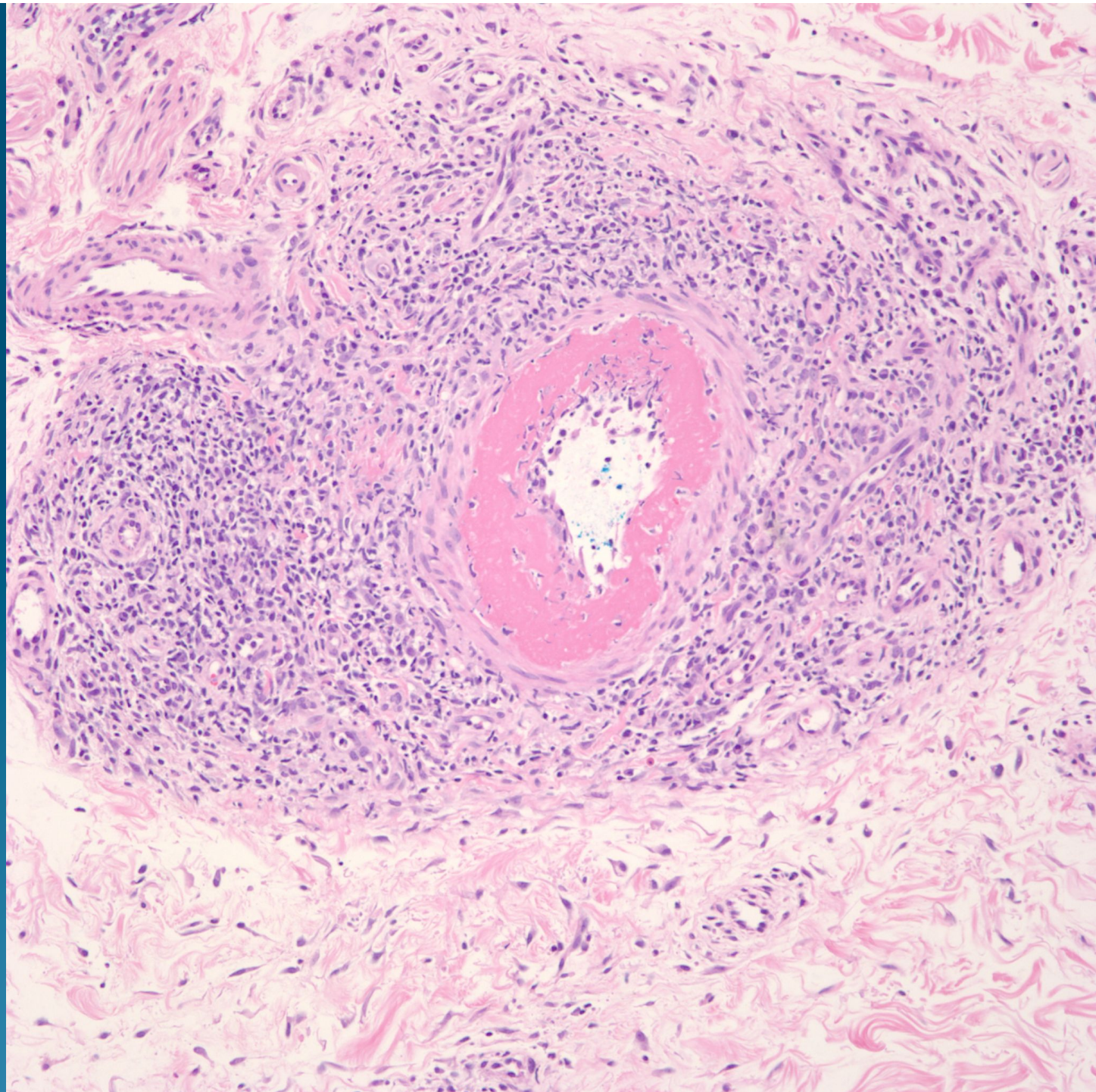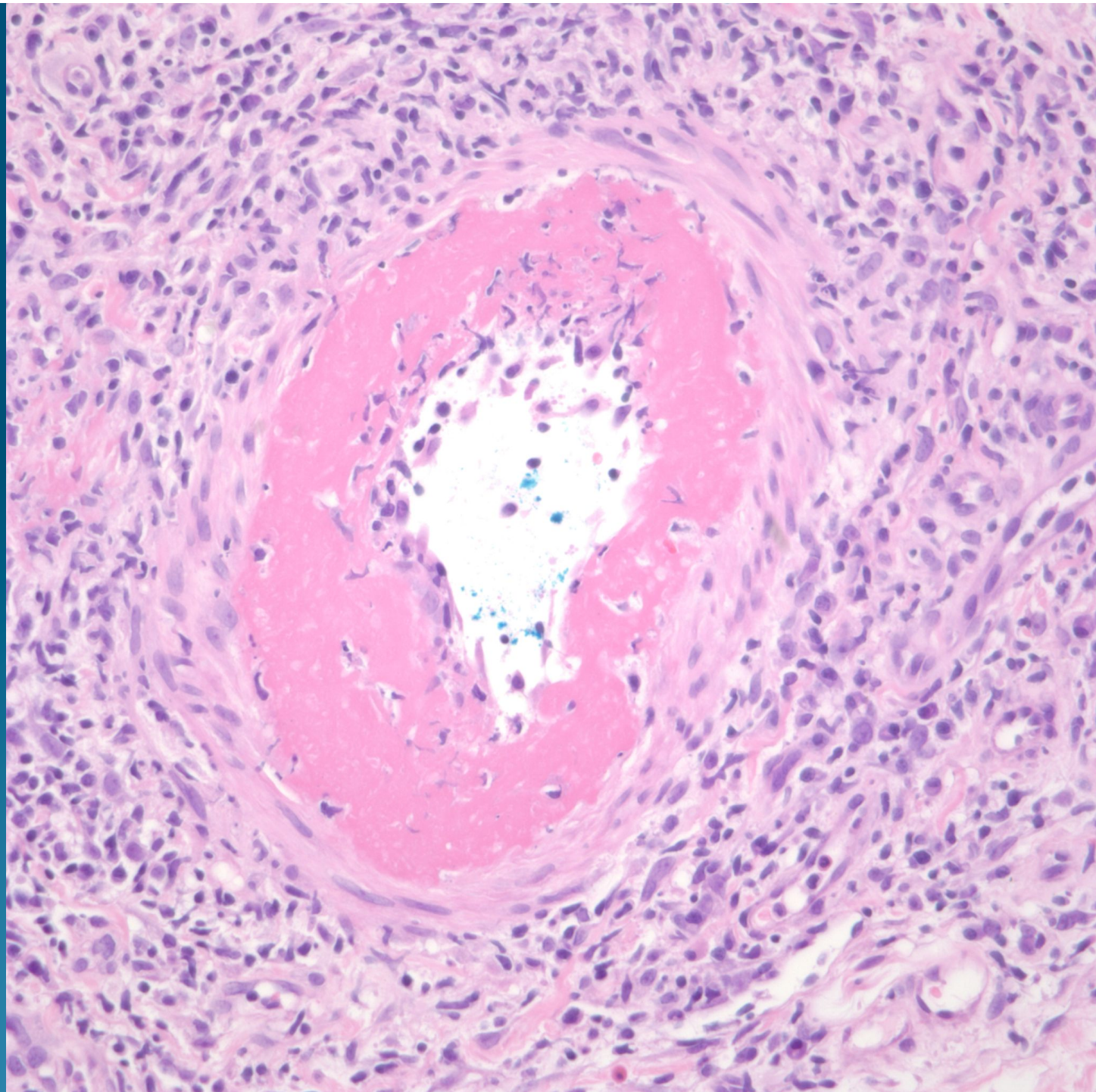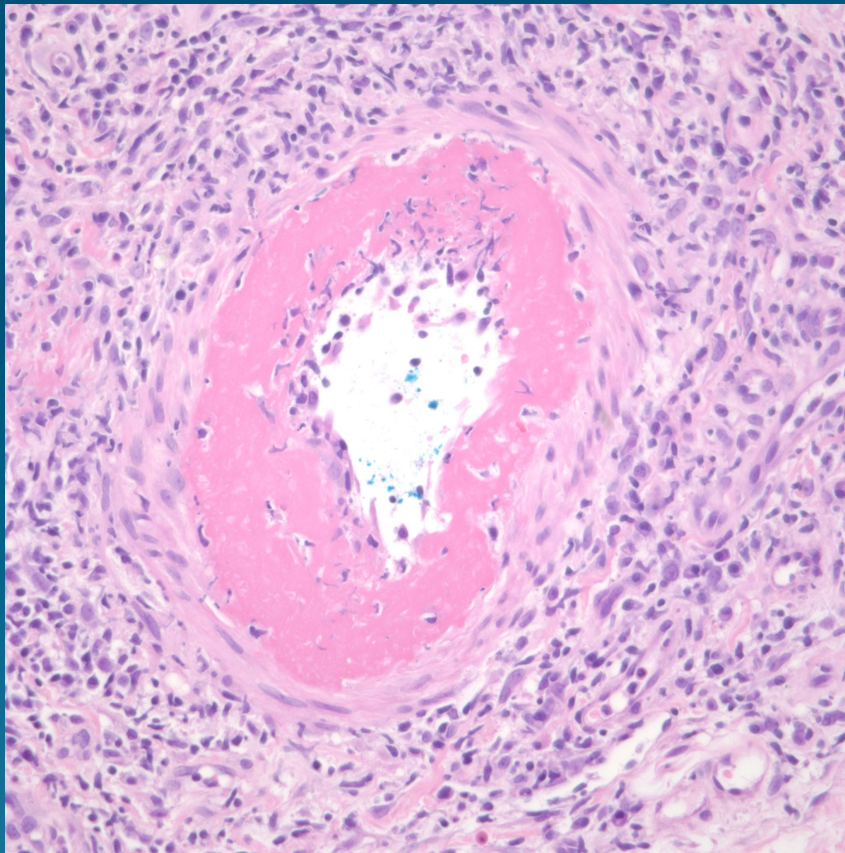


What is the diagnosis?

Lymphocytic Thrombophilic Arteritis

Pearls



- Concentric fibrin ring involving the periphery of the lumina of affected vessels usually at junction of subQ fat
- Clinical presentation of livedo racemosa in lower limbs
- 4/5 patients with serum Antiphospholipid antibodies